



Non-Surgical Endodontic Retreatment of Anterior Tooth with Open Apex: A Report of Two cases

Abdulelah Sameer Sindi; Youssef A Algarni; Suheel Manzoor Baba; Shafait ullah Khateeb

Assistant Professor Department of Restorative Dental Science College of Dentistry, King Khalid University Abha
Saudi Arabia

E-mail: asindi@kku.edu.sa; yalgarni@kku.edu.sa; baba@kku.edu.sa; skhateeb@kku.edu.sa

<http://dx.doi.org/10.47814/ijssrr.v6i3.953>

Abstract

The main reason for an endodontic failure is the persistence or regrowth of bacteria within the root canal system. Retreatment of such cases is needed to irradiate the bacteria from the canals. Endodontic retreatment of a tooth with open apex can be a challenge because of difficulty in obtaining an apical seal, and existing thin radicular walls which are susceptible to fracture. An apical barrier with calcium hydroxide has been the treatment of choice for such cases previously. But due its disadvantages MTA has gained popularity in dealing with such cases with blunderbuss canal and open apex. This article presents two case reports of failed root canal treatment of central incisors which were successfully managed with non-surgical retreatment.

Keywords: *Apexification; MTA; Open Apex; Retreatment*

Introduction

The management of teeth with open apex can be a challenge in endodontic practice.

There is change in apical foramen anatomy with age as root formation has yet to be completed. For root formation to complete and apex closure it may take up to three years (1). Open apex formation can occur in certain instances when the process of apex closure is disturbed in permanent teeth

Open apex is usually of two types Blunderbuss and non-blunderbuss. Endodontic treatment of permanent tooth with blunderbuss canal can be an endodontic challenge because of parallel root canal walls with broad apex making preparation of root canals very difficult and formation of an in effective apical seal (2). Hence to allow compaction of root canal filling material an apical barrier will be needed in such cases to develop an adequate apical seal.

Traditionally application of calcium hydroxide ($\text{Ca}(\text{OH})_2$) has been used for inducing apexification in immature permanent teeth with open apices. Unfortunately use of calcium hydroxide comes with several disadvantages such as long time span to complete treatment, risk of re infection because of loss of interim restoration, “Swiss cheese” porous callus bridge formation, inability to promote continued root development and thickness of lateral dentinal walls, and a high pH which promotes necrotic and degenerative changes in the apical tissue in contact (3,4,5). To overcome these shortcomings “one visit apexification” with mineral trioxide aggregate (MTA) was introduced.

Mineral trioxide aggregate (MTA) has progressed as a material of choice for apexification because of its properties such as biocompatibility, excellent sealing ability, Regeneration of pulp, and peri-radicular tissue (6,7). Moreover because of its hydrophilic property MTA sets in presence of moisture. These case reports describe successful non-surgical retreatment with MTA of previously failed root canal treatment (7).

Case Reports

Case 1

A 29-year-old male patient came to our specialty clinic with chief complaint of pain on biting in upper anterior region. Clinical investigation revealed discoloration of maxillary left central incisor. No pain and tenderness on palpation and percussion was noted. There was no mobility in the tooth. Radiograph showed an improper obturation with lack of apical seal (FIG1). A diagnosis of previous root canal treated with asymptomatic apical periodontitis was made.

An apical plug with MTA was considered as treatment plan because of width of apex.

Patient was informed with the treatment plan and a consent was taken from the patient.

Local anesthesia with 2% lignocaine with epinephrine (1:100000) was administered followed by rubber dam application. A round bur was used to remove the restoration from the access cavity. The bulk of gutta-percha was removed using the universal ProTaper retreatment Files (D1-D3) (Dentsply Maillefer).

This was followed by the use of gutta percha solvent along with hand H-Files in circumferential motion to facilitate the removal of the residual root canal filling.

A working was confirmed with an apex locator and confirmed with an x ray (FIG 2). The canal was thoroughly debrided with a copious irrigation of 3-5 ml sodium hypochlorite (3%), 3 ml of 2% chlorhexidine. The canal was dried with sterile paper points, and calcium hydroxide dressing was placed in the canal. The access was sealed with a temporary restoration and patient was recalled after 1 week.

After 1 week calcium hydroxide was removed from the canal. The shaping and irrigation protocol was repeated as earlier. The canal was dried using paper point and Pro root MTA (Dentsply) was mixed as per manufacturer instruction and carried with MAP system into the root canal. A radiographic was taken to check the correct positioning of the MTA material. 5 mm thick MTA was packed into the apical segment which was confirmed on x ray (FIG 3). A moistened cotton pellet was placed in orifice followed with a temporary. The patient was recalled next day and once the hardness of apical plug was confirmed the remaining canal was obturated using Obtura (FIG 4). Access was sealed with GIC.

The patient was referred to prosthodontist for crown placement.

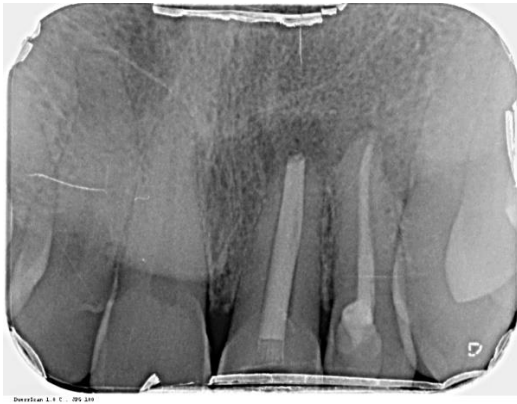

FIG 1

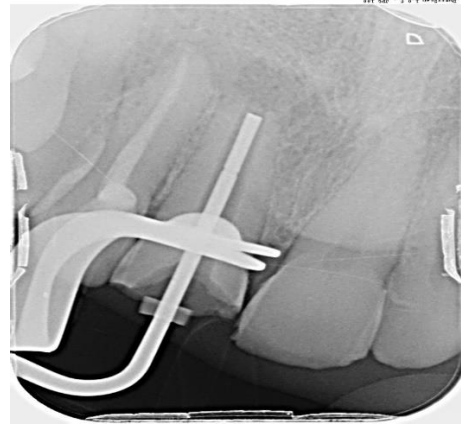


FIG 2

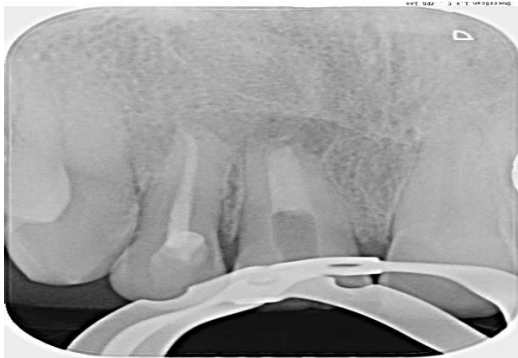

FIG 3

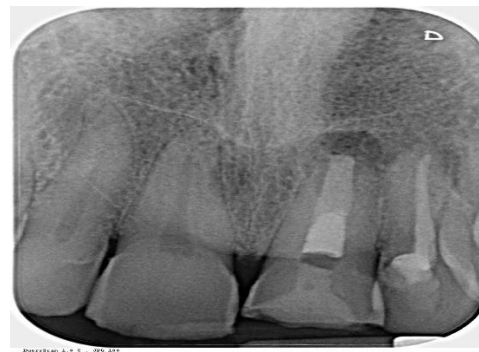

FIG 4

Case 2

A 34-year-old male patient came to our specialty clinic complaining from pain and mobility in upper anterior area. On Clinical examination a ceramic crown was observed on maxillary left central incisor. There was mild pain on palpation and percussion. Grade 1 mobility was observed with the tooth. A periapical radiograph showed an inadequate root canal filling with lack of apical seal with lateral radiolucency (FIG 1). A diagnosis of previous root canal treated with asymptomatic apical periodontitis was made.

Removal of the crown followed by retreatment with MTA apical plug formation was planned and an informed consent was taken from the patient.

After removal of crown, Rubber dam was applied the access cavity with cleaned off any restoration with a round bur. Gutta percha was retrieved from the canal using Pro taper retreatment files and solvent. The bulk of gutta percha was retrieved with H file (FIG 2)

A working was confirmed with an apex locator and confirmed with an x ray (FIG 3). The canal was thoroughly debrided with a copious irrigation of 3-5 ml sodium hypochlorite (3%), and 3 ml of 2% chlorhexidine. The canal was dried with sterile paper points, and a calcium hydroxide dressing was placed in the canal. The access was sealed with a temporary restoration and patient was recalled after 1week. After 1 week calcium hydroxide was removed from the canal. The shaping and irrigation protocol was repeated as previously. The canal was dried using paper point and Pro root MTA (Dentsply) was mixed as per manufacturer instruction and carried with MAP system into the root canal. A radiographic was

taken to check the correct positioning of the MTA material (FIG 4). 5 mm thick MTA was packed into the apical segment which was confirmed on x ray. A moistened cotton pellet was placed in orifice followed with a temporary. The patient was recalled next day and once the hardness of apical plug was confirmed the remaining canal was obturated using Obtura (FIG 5). Access was sealed with GIC .

Patient was recalled after 3 months and complete healing of peri apical lesion was observed (FIG 6)

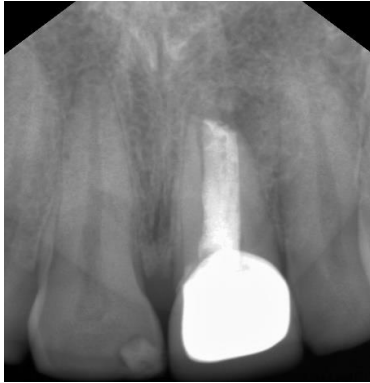

FIG 1

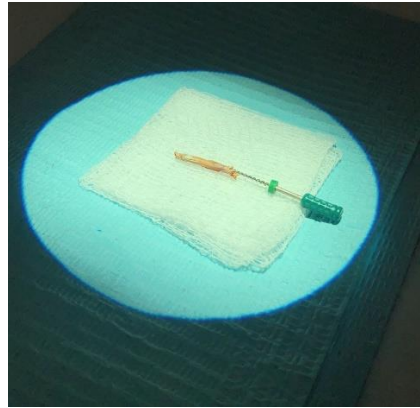


FIG 2

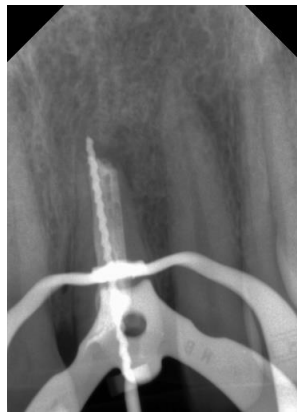

FIG 3

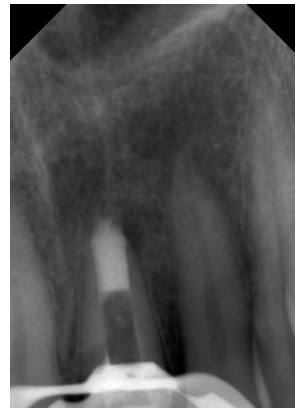

FIG 4

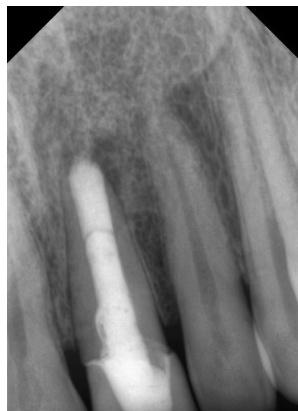

FIG 5

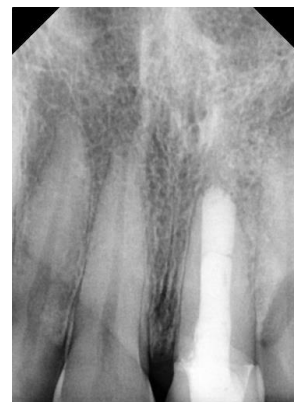

FIG 6

Discussion

The rationale of endodontic treatment is to eradicate infections from the root canal system and prevent microorganisms from infecting or re-infecting the root canal system(8,9,10). An immature permanent incisor tooth is considered as a tooth with an open apex. Before a root canal treatment of such teeth is done a root end closure procedure to form an apical barrier is required against with which a root canal filling with a sealer can be condensed (11).

Previously a long term calcium hydroxide medicament therapy to induce a calcific barrier was the most common procedure to create an apical seal in such cases (12). No doubt this technique has proved to be a successful method clinically but it comes with several disadvantages such as longer time period needing compliance of patient, reinfection possibility and tooth fracture during or after treatment (13,14,15).

One-visit apexification by an artificial apical plug technique with MTA has proven to be alternate method. MTA has shown better physio chemical properties like biocompatibility, better marginal adaptation and has antibacterial action with a shorter setting time and high clinical success in comparison to calcium hydroxide apexification (16,17).

Because of these properties MTA was used to create an apical barrier in both these cases.

In these cases Pro Root MTA (Dentsply sirona) was used . The required amount of powder pro root liquid to desired consistency and was place in to the root canal with MAP system. A radiograph was taken to confirm the positioning of MTA. MTA being hydrophilic a moistened cotton pellet is advised to be place to allow hardening of MTA and permanent filling in second visit (18).

As has been reported in earlier cases, the use of MTA has demonstrated clinical and radiographic success at follow up controls. In our case after apexification with MTA has shown healing of the periapical lesion in 3 months interval post apexification hence confirming the evidence that MTA creates a good biological seal thereby preventing infection and reinfection of root canals.

An apical plug can be a treatment choice for management of teeth with incomplete root formation in need of an immediate restoration

Conclusion

MTA is the material of choice in today's clinical practice. Its use in Endodontics ranges from apexification, perforation repair to apical surgery procedures. The main advantages of MTA is when it is used as an apical plug, it can be done in single appointment, good biocompatibility and develop a hermetic apical seal with no micro leakage. The above case reports have shown use of MTA in apexification procedure and it ensures that MTA can be used as an apical barrier & considered as highly effective for treatment of immature non vital permanent teeth with open apex.

References

1. American Association of Endodontists. Glossary of endodontic terms,7thedn. Chicago:American Association of Endodontists; 2003.
2. Andreasen JO, Farik B, Munksgaard EC. Long-term calcium hydroxide as a root canal dressing may increase risk of root fracture. Dent Traumatol. 2002.
3. Rotstein I, Friedman S, Katz J. Apical closure of mature molar roots with the use of calcium hydroxide. Oral Surg Oral Med Oral Pathol. 1990;70:656–60.

4. Torabinejad M, Abu-Tahun I. Management of teeth with necrotic pulps and open apices. *Endod Topics*. 2012;23:105–10.
5. Torabinejad M, Chivian N. Clinical applications of mineral trioxide aggregate. *J Endod* 1999;25:197–205.
6. Mirhadi H, Moazzami F, Jahromi SR, et al. The effects of alkaline PH on microleakage of mineral trioxide aggregate and calcium enriched mixture apical plugs. *J Dent (Shiraz)* 2016;;17((1)):16—20.
7. Torabinejad M, Parirokh M. Mineral trioxide aggregate: a comprehensive literature review–part II: leakage and biocompatibility investigations. *J Endod* 2010;36:190–202.
8. Saleh IM, Ruyter IE, Haapasalo M, Ørstavik D. Survival of *Enterococcus faecalis* in infected dentinal tubules after root canal filling with different root canal sealers in vitro. *Int Endod J* 2004;37:193-8.
9. L Lakshmi Narayanan, C Vaishnavi. Endodontic microbiology; *J Conserv Dent*. 2010 Oct-Dec; 13(4): 233–239.
10. Jasmine Wong, Daniel Manoil, Peggy Näsman, Georgios N. Belibasakis, Prasanna Neelakantan. Microbiological Aspects of Root Canal Infections and Disinfection Strategies: An Update Review on the Current Knowledge and Challenges; *Front Oral Health*. 2021; 2: 672887.
11. SC Harlamb: Management of incompletely developed teeth requiring root canal treatment; *Australian Dental Journal* 2016; 61:(1 Suppl): 95–106.
12. Corbella S, Ferrara G, El Kabbaney A, Taschieri S. Apexification, apexogenesis and regenerative endodontic procedures: a review of the literature. *Minerva Stomatol* 2014;63:375–89.
13. Rafter M. Apexification: a review. *Dent Traumatol* ;2005;21:1–8.
14. Torabinejad M, Rastegar AF, Kettering JD, Pitt Ford TR. Bacterial leakage of mineral trioxide aggregate as a rootend filling material. *J Endod* 1995;21:109–12.
15. Kahler SL, Shetty S, Andreasen FM, Kahler B. The Effect of Long-term Dressing with Calcium Hydroxide on the Fracture Susceptibility of Teeth. *J Endod* 2018;44:464–69.
16. Simon S, Rilliard F, Berdal A, Machtou P. The use of mineral trioxide aggregate in one-visit apexification treatment: a prospective study. *Int Endod J* 2007;40:186–97.
17. Torabinejad M, Pitt Ford TR. Root end filling materials: a review. *Endod Dent Traumatol* 1996;12:161–78.
18. Danesh G, Dammaschke T, Gerth HU, Zandbiglari T, Schäfer E. A comparative study of selected properties of ProRoot mineral trioxide aggregate and two Portland cements. *Int Endod J* 2006;39:213-9.

Copyrights

Copyright for this article is retained by the author(s), with first publication rights granted to the journal.

This is an open-access article distributed under the terms and conditions of the Creative Commons Attribution license (<http://creativecommons.org/licenses/by/4.0/>).